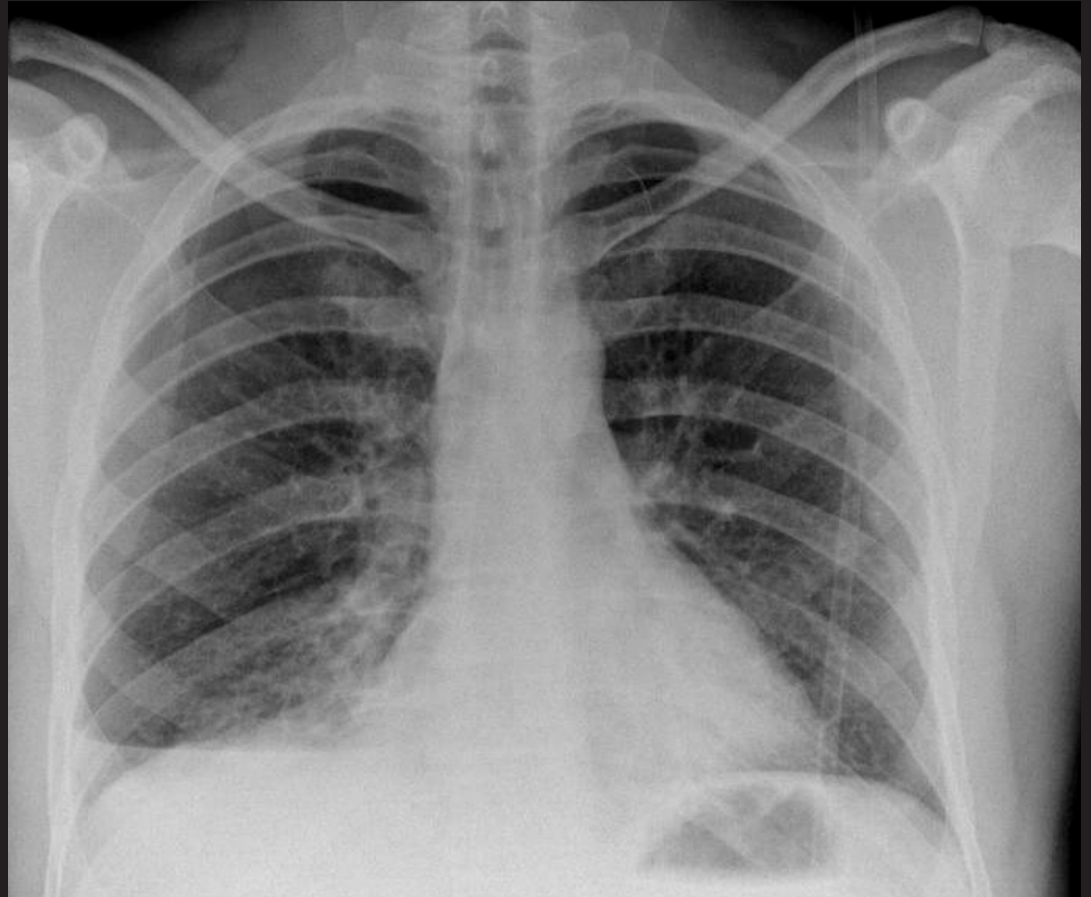
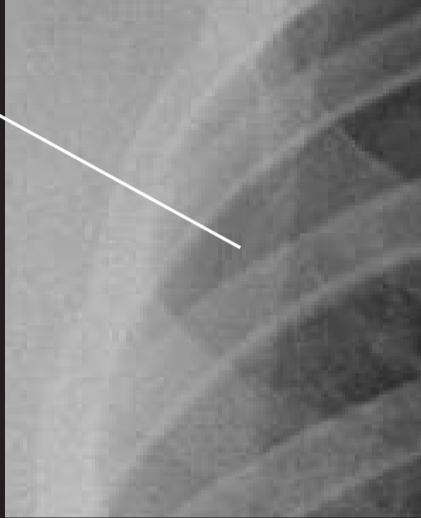

Haemopneumothorax.

Chest x-ray and axial thoracic CT image of a young cyclist who sustained a traumatic right pneumothorax when he came off his bike.

Lung edge



Air in pleural space



Partially collapsed right lung



Blood lying posteriorly in pleura

